

Surgical Management of Duodenal Perforation in a Patient With Gardner Syndrome and Abdominal Wall Reconstruction

Kelsey Murray^a, Jean Luc Francois^a, Saamia Shaikh^{a, b},
Ahmad Hlayhel^a, Toghrul Talishinskiy^a

Abstract

Duodenal perforation is a rare complication of esophagogastroduodenoscopy (EGD) and may be caused by direct injury from the endoscope during the procedure. This complication has a relatively high mortality rate but can be reliably managed with surgical repair. We present the case of a young man with Gardner syndrome who obtained a duodenal perforation during a surveillance EGD with endoscopic mucosal resection (EMR). Our patient was deemed a poor surgical candidate due to previous excision of a large abdominal wall desmoid tumor with cadaveric graft reconstruction that in turn created limited access for any subsequent abdominal surgeries. As such, he underwent multiple failed endoscopic repairs before definitive surgical management with a Graham patch repair using a unique entry approach. This case highlights the treatment course of this rare patient.

Keywords: Duodenal perforation; Gardner syndrome; Abdominal wall reconstruction

Introduction

Familial adenomatous polyposis (FAP) is a familial cancer syndrome caused by mutation of the adenomatous polyposis coli tumor suppressor gene located on chromosome 5 [1]. While most cases are due to autosomal dominant inheritance, up to 30% of cases are due to new or germline mutations [1, 2]. This syndrome is defined by its presentation of over 100 colorectal polyps detected by the third decade of life [1]. This significant polyposis carries a 100% risk of carcinogenesis by age 45 which necessitates prophylactic proctocolectomy [1].

Gardner syndrome is a phenotypic variant of FAP, which is characterized by a triad of colonic polyposis, multiple osteomas, and mesenchymal tumors of the skin and soft tissue, namely desmoid tumors [2]. These tumors cause significant morbidity and mortality in 29% of patients due to local aggressiveness and high recurrence rates after resection [3]. Additionally, these patients have an increased incidence of gastric and duodenal polyps with an almost 100% lifetime risk of developing duodenal adenomas [4]. While the gastric polyps are usually benign, the duodenal polyps carry a 5% lifetime risk of transformation to duodenal cancer, which is one of the leading causes of mortality in these patients [4]. To standardize the management of the duodenal polyposis, the Spigelman classification system was developed. This classification system categorizes polyps based on their size, number, histology, and dysplasia from stage 0 to stage 4 which provides information about the risk of malignant transformation and guides endoscopic surveillance and prophylactic measures to prevent malignancy [4]. Management involves esophagogastroduodenoscopy (EGD) for removal or destruction using standard polypectomy and local ablation techniques [4]. Of the complications that can occur during this procedure, duodenal perforations are the most lethal, carrying a mortality of 8-25% [5]. However, due to the overall infrequency of this complication, there are no definitive guidelines for their management [6-8].

To further complicate matters, the patient developed a frozen abdomen with loss of domain of his abdominal reconstruction with overlying skin graft. Herein, we present the rare case of a 39-year-old man with Gardner syndrome and extensive prior abdominal reconstruction who presented post EGD with duodenal perforation. Despite initial attempts at endoscopic repair, the perforation ultimately required surgical repair using a unique vertical incision at the lateral abdominal edge.

Case Report

The patient is a 39-year-old male who presented to the emergency department with severe progressive abdominal pain that began shortly after he underwent EGD with endoscopic mucosal resection (EMR) for resection of D2 polyps the day prior. His medical history included recently diagnosed Gardner syndrome and an extensive past surgical history of desmoid tumor resections requiring a large abdominal wall resection. His

Manuscript submitted July 12, 2021, accepted July 28, 2021
Published online September 30, 2021

^aDepartment of Surgery, St. Joseph's University Medical Center, Paterson, NJ 07503, USA

^bCorresponding Author: Saamia Shaikh, Department of Surgery, St. Joseph's University Medical Center, 703 Main Street, Paterson, NJ 07503, USA.
Email: r_shaikhs@sjhmc.org

doi: <https://doi.org/10.14740/jcs443>

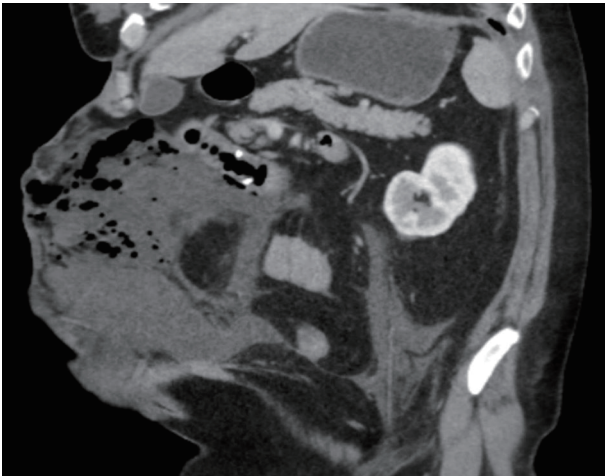


Figure 1. Computed tomography (CT) of abdomen and pelvis with intravenous contrast showing the site of perforation in the duodenum.

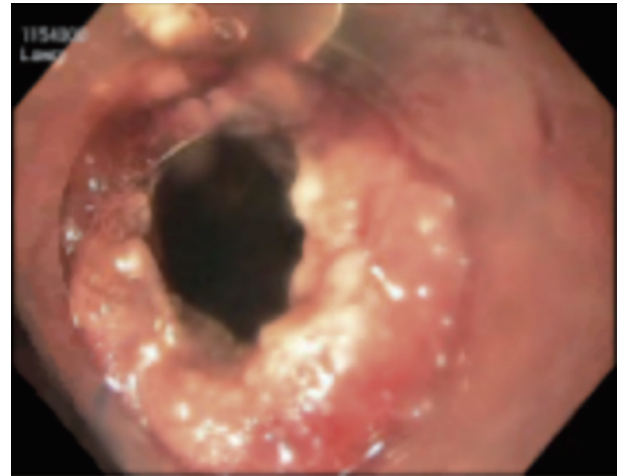

Figure 2. Esophagogastroduodenoscopy showing the 15 × 10 mm duodenal perforation.

medical course was further complicated by the development of a large ventral hernia due to significant tissue removal from the anterior abdominal wall which required reconstruction with a cadaveric skin graft.

Due to the patient's later in life diagnosis of Gardner syndrome at the age of 38, he did not have a prophylactic colectomy prior to his abdominal reconstruction, which created poor surgical access for any subsequent abdominal surgeries. The decision was therefore made to pursue colonic surveillance endoscopically with resection of polyps as needed to mitigate his risk of colon cancer in addition to the recommended EGDs which ultimately led to his current admission.

On presentation, the patient was tachycardic, tachypneic, and complained of diffuse abdominal pain. He had a diffusely tender frozen abdomen with loss of abdominal domain as well as large ventral hernia with overlying skin graft. Laboratory investigations were notable for a white blood cell (WBC) count of 15,900 cells/ μ L and lactic acid of 3.8 mmol/L. Computed tomography of his abdomen and pelvis revealed free intraperitoneal air and fluid (Fig. 1) along with a defect in the distal duodenum compatible with a perforation (Fig. 2). He subsequently underwent an EGD for localization and attempted primary repair of a 15-mm duodenal perforation. This was unsuccessful and the patient underwent two additional endoscopic repair attempts which utilized a combination of suturing, over-the-scope clips, and Vicryl mesh packing.

Additionally, he developed an expanding intra-abdominal fluid collection that persisted despite interventional radiology (IR) drainage. At this point, the decision was made to attempt surgical repair of the duodenal perforation. A laparoscopic Graham patch repair via step-up approach was initially planned to help preserve the vascular integrity of his cadaveric skin graft. This involved immobilizing the patient in left lateral decubitus and entering the abdomen laterally through the existing IR drain site. Due to extensive adhesions, the procedure was converted to an exploratory laparotomy using a vertical incision at the junction of graft and body wall on the right side. The 15 × 10 mm defect was located on the posterolateral aspect of D2 and repaired using a patch from the greater omentum. Plastic

surgery then created a complex rotational advancement flap for closure of the abdominal wall. He did also require revision of the abdominal closure on postoperative day 8. Nevertheless, postoperative imaging was negative for any evidence of leak. There were no further complications, and the patient was discharged on postoperative day 23 with instructions to follow-up outpatient. This work has been reported in line with the SCARE criteria [9].

Discussion

The overall risk of complications from EGD is quite low, occurring in approximately 1.3% of cases [6]. However, the need for frequent EGD in patients with Gardner syndrome puts this patient population at an increased risk of experiencing complications from these procedures [4]. Perforation is the most serious complication with a reported mortality between 8-25% [5]. These perforations may occur at any point in the upper gastrointestinal tract; however, duodenal perforations carry the highest mortality [6]. Based on the Stapfer classification of endoscopic retrograde cholangiopancreatography (ERCP)-related duodenal perforations, EGD perforations may either be type 1 or type 4 perforations as there is no biliary instrumentation [7, 8]. Type 1 perforations are lateral or medial wall perforations directly caused by the endoscope [7, 8]. These perforations are associated with serious consequences as they cause significant intestinal content leakage into peritoneal and retroperitoneal spaces, which may quickly progress to peritonitis, retroperitoneal necrosis, sepsis and multi-organ failure [6]. Conversely, type 4 perforations are small retroperitoneal perforations often attributed to pneumatosis intestinalis forced into the duodenum that translocate to the retroperitoneum [7, 8].

Our patient presented with a type 1 duodenal perforation. Surgical intervention is warranted when there is evidence of overt peritonitis or extravasation of oral contrast, which is often seen in type 1 perforations [6-8]. However, due to our patient's large anterior wall reconstruction and hemodynamic

stability, an endoscopic approach was initially utilized. While surgery remains the management of choice, there has been increased use of endoscopic management for this complication of EGD [7]. It is an attractive option as it often circumvents the need for surgical exploration while allowing for primary closure of the defect [6]. Furthermore, when used in the management of early perforations, defined as perforations visualized during the initial endoscopic procedure, repair can be attempted immediately which greatly reduces the amount of intestinal content that leaks through the defect [10].

However, as seen in our case, perforations often go unnoticed initially, leading to delayed presentation after significant leakage of intestinal contents causing systemic inflammatory response syndrome (SIRS) and infection with subsequent sepsis [10]. While retrospective studies are small, it is estimated that between 40% and 90% of perforations may be missed during the initial procedure, thus minimizing the utility of this advantage [10]. The main limitations of this method of intervention are defect size and operator experience. Larger defects are less likely to be amenable to endoscopic repair, and success of the intervention is highly dependent on skill level [6, 10]. Despite this, some sources recommend this intervention for cases with localized peritonitis or contrast extravasation from the defect [6]. If done by a skilled operator, this intervention is successful in up to 90% cases [6, 10].

Surgical management is often the definitive management of EGD-related duodenal perforations and typically involves using an omental patching technique to seal the defect [6-8, 10]. Despite limited abdominal access in our case, the need for surgical intervention led to a modified approach in entering the abdominal cavity. Our initial approach utilized principles from laparoscopic necrosectomy used in the step-up approach for managing necrotizing pancreatitis. In laparoscopic necrosectomy of step-up approach, the patient is placed in left lateral decubitus position using a bean bag to allow for better access to the lesser sac. Then, the laparoscope is inserted using the existing IR drainage site for insertion of the laparoscope [11]. In our case, however, it was deemed necessary to convert to an open procedure. For this, we made a vertical incision at the junction of graft and body wall on the right to preserve the vascular integrity of the graft. To the best of our knowledge, this unique approach for a Graham patch repair for a duodenal perforation has never been documented in the literature.

Conclusions

Our patient's persistent duodenal perforation posed a great challenge particularly when complicated by his abdominal graft tissue, clinical state, as well as his comorbidities. The endoscopic approach was found to be insufficient, leading us to attempt a Graham patch repair using modified entry. As highlighted by our case, surgical management is often definitive for managing type 1 duodenal perforations. We therefore recommend initial surgical intervention with modified entry for the repair of type 1 perforations in cases of difficult abdominal access. This recommendation would prevent delays in management which are associated with worse outcomes.

Acknowledgments

None to declare.

Financial Disclosure

None to declare.

Conflict of Interest

The authors declare no conflict of interest.

Informed Consent

Informed consent was obtained and all identifying information has been omitted.

Author Contributions

All authors have participated in the intellectual content and analysis of data. All of the authors have reviewed the final version of the manuscript and have approved it for publication.

Data Availability

The authors declare that data supporting the findings of this case report are available within the manuscript.

Abbreviations

EGD: esophagogastroduodenoscopy; EMR: endoscopic mucosal resection; FAP: familial adenomatous polyposis; WBC: white blood cell; IR: interventional radiology; ERCP: endoscopic retrograde cholangiopancreatography; SIRS: systemic inflammatory response syndrome

References

1. Beech D, Pontius A, Muni N, Long WP. Familial adenomatous polyposis: a case report and review of the literature. *J Natl Med Assoc.* 2001;93(6):208-213.
2. Fotiadis C, Tsekouras DK, Antonakis P, Sfiniadakis J, Genetzakis M, Zografos GC. Gardner's syndrome: a case report and review of the literature. *World J Gastroenterol.* 2005;11(34):5408-5411.
3. Chung J, Namkoong S, Jung KE, Park JW, Park BC, Cinn YW, Kim MH. A case of Gardner's syndrome associated with desmoid tumor. *Ann Dermatol.* 2010;22(4):418-421.
4. Campos FG, Sulbaran M, Safatle-Ribeiro AV, Martinez

- CA. Duodenal adenoma surveillance in patients with familial adenomatous polyposis. *World J Gastrointest Endosc.* 2015;7(10):950-959.
5. Amini A, Lopez RA. Duodenal perforation. [Updated Apr 14, 2020]. In: StatPearls [Internet]. Treasure Island (FL): StatPearls Publishing. 2020.
 6. Chertoff J, Khullar V, Burke L. Duodenal perforation following esophagogastroduodenoscopy (EGD) with cautery and epinephrine injection for peptic ulcer disease: An interesting case of nonoperative management in the medical intensive care unit (MICU). *Int J Surg Case Rep.* 2015;10:121-125.
 7. Rabie ME, Mir NH, Al Skaini MS, El Hakeem I, Hadad A, Ageely H, Shaban AN, et al. Operative and non-operative management of endoscopic retrograde cholangiopancreatography-associated duodenal injuries. *Ann R Coll Surg Engl.* 2013;95(4):285-290.
 8. Turner RC, Steffen CM, Boyd P. Endoscopic duodenal perforation: surgical strategies in a regional centre. *World J Emerg Surg.* 2014;9(1):11.
 9. Agha RA, Borrelli MR, Farwana R, Koshy K, Fowler AJ, Orgill DP, For the SCARE Group. The SCARE 2018 statement: Updating consensus Surgical CAse REport (SCARE) guidelines. *Int J Surg.* 2018;60:132-136.
 10. Bill JG, Smith Z, Brancheck J, Elsner J, Hobbs P, Lang GD, Early DS, et al. The importance of early recognition in management of ERCP-related perforations. *Surg Endosc.* 2018;32(12):4841-4849.
 11. Parekh D. Laparoscopic-assisted pancreatic necrosectomy: A new surgical option for treatment of severe necrotizing pancreatitis. *Arch Surg.* 2006;141(9):895-902; discussion 902-893.